




Contents lists available at ScienceDirect

## Asian Pacific Journal of Tropical Biomedicine

journal homepage: [www.elsevier.com/locate/apjtb](http://www.elsevier.com/locate/apjtb)

## Document heading

# Pharmacological evaluation of ethanolic extract of *Daucus carota* Linn root formulated cream on wound healing using excision and incision wound model

Mithun Vishwanath K Patil<sup>1\*</sup>, Amit D Kandhare<sup>2</sup>, Sucheta D Bhise<sup>1</sup><sup>1</sup>Abhinav College of Pharmacy, Narhe, Pune-411043, Maharashtra, India<sup>2</sup>Department of Pharmacology, Poona college of Pharmacy, Bharati Vidyapeeth Deemed University, Pune-411038, Maharashtra, India

## ARTICLE INFO

## ABSTRACT

**Article history:**

Received 25 June 2012

Received in revised form 5 July 2012

Accepted 7 August 2012

Available online 28 August 2012

**Keywords:**

Antioxidants

Cream

*Daucus carota*

Excision wounds

Framycine sulfate cream

Hydroxyproline content

Incision wounds

Protein content

Tensile strength

Wound contraction

**Objective:** *Daucus carota* L. (Carrot) (Apiaceae) is used in the traditional medicine for the treatment of variety of ailments. The aim of present investigation was to formulate and evaluate wound healing activity of ethanolic extract of *Daucus carota* L. root on excision wound model and incision wound model. **Methods:** The soft paraffin based cream containing 1%, 2% and 4% w/w of ethanolic extract of *Daucus carota* L. (EEDC) root was formulated and evaluated for pharmaceutical parameters such as rheological properties, pH, skin irritation and external characters. Excision wounds sized 300 mm<sup>2</sup> and 2 mm depth were used for the study of rate of contraction of wound and epithelization at different time intervals. Incision wounds six centimeter long and two linear–paravertebral incisions were used for the study of tensile strength, total protein and hydroxyproline content measured on 10th day old incision wound. **Results:** Ethanolic extract of *Daucus carota* L. root cream formulation when applied topically did not show any sign and symptoms of skin irritation. Animals treated with topical EEDC cream formulation (1%, 2% and 4% w/w) showed significance decrease in wound area, epithelization period and scar width whereas rate of wound contraction significantly increased ( $P < 0.01$ ,  $P < 0.001$  and  $P < 0.001$  resp.) as compared to control group animals in excision wound model. In incision wound model there was significant increase ( $P < 0.01$  and  $P < 0.001$ ) in tensile strength, hydroxyproline content and protein content of animals treated with topical EEDC cream formulation (2% and 4% w/w, respectively). **Conclusions:** Wound–healing property of ethanolic extract of *Daucus carota* L. root may be attributed to the various phytoconstituents like flavonoids and phenolic derivatives present in the root and the quicker process of wound healing could be a function of either its antioxidant or antimicrobial potential. The present findings provide scientific evidence to the ethanomedicinal properties of *Daucus carota* in wounds healing activity.

## 1. Introduction

An array of etiopathogenic factors contribute to the development of wounds including physical or chemical injury as well as microbial infections. Wounds are indispensable part of life. Wound healing is a complex and dynamic process in which cellular structure and tissue layer of the damaged tissue are restored to its normal state as closely as possible<sup>[1]</sup>.

Wound contracture is a part of healing process involved migration of the fibroblast to the injured tissue which followed

by shrinkage of the wound area. The type and extent of damage, the general state of the host's health and the ability of the tissue to repair have been elucidated for rate of extent of wound healing. Inflammatory, proliferative and maturational are the three different phases of wound healing. Hemostasis and inflammation are the two different characteristic stages of inflammatory phase whereas; proliferative phase is comprised of epithelization, angiogenesis and collagen deposition. Appearance of small amount of scar tissue during the contraction of the wound is the characteristic feature of the maturational phase<sup>[2]</sup>.

After tissue damage the sequence of biochemical changes occurred at the site of injury in which various components of blood migrate to the site of injury. Activated platelets

\*Corresponding author: Mithun Vishwanath K. Patil, Abhinav College of Pharmacy, Narhe, Pune- 411043, Maharashtra, India.  
E-mail: [mithunpatil7@gmail.com](mailto:mithunpatil7@gmail.com)

react with exposed collagen and other elements resulted in release of clotting factors as well as essential growth factors<sup>[3]</sup>. The neutrophils plays vital role to remove foreign materials, bacteria and damaged tissue by means of phagocytosis which continues by macrophages. After completion of the phagocytosis, tissue formation process begins in presence of the fibroblasts which deposit new extracellular collagen matrix. The final remodeling phase involves cross-linking and organization of newly formed collagen matrix<sup>[4]</sup>.

Wound healing is a natural process and requires no help to be completed. But for the rapid healing of wound there is need to provide better conditions that can regenerate the damaged tissues<sup>[5]</sup>. Management of under healing of wounds is a complicated and expensive program and research on drugs that increase wound healing is a developing area in modern biomedical sciences<sup>[6,7]</sup>. Therefore an array dosage form including ointment, cream, jellies and sprays containing of various drugs which possess wound healing and antimicrobial potential has been implicated in the management of the wound healing<sup>[8,9]</sup>.

Synthetic chemical moieties are the present treatment regimens for the management of under healing of wound but they possess a wide range of side effects. Therefore research has prompted into herbal and natural products which known to increase the healing of different types of wounds and which can eliminate the side effects that were associated with the synthetic chemical moieties<sup>[10]</sup>. Though some of these drugs have been screened scientifically for evaluation of their wound healing activity in different pharmacological models and patients<sup>[11]</sup>, the potential of many of the traditionally used herbal agents remains unexplored. In few cases, active chemical constituents were identified<sup>[12]</sup>. Hence there is need to identify the various plants or their chemical entities and formulated them for treatment and management of wounds.

In the traditional system of medicine *Daucus carota* plant has been used as a diuretic and inotropic, cystitis, gout and lithuria<sup>[13,14]</sup>. Scientific studies have shown that extract obtained from various parts of the *Daucus carota* plant possesses analgesic and anti-inflammatory<sup>[15]</sup>, hepatoprotective<sup>[16]</sup>, hypoglycemic<sup>[17]</sup>, antiulcer<sup>[18]</sup>, antifertility<sup>[19]</sup>, anticancer<sup>[20]</sup>, anti-tumor<sup>[21]</sup>.

Hence the objective of present investigation was to unravel therapeutic potential of ethanolic extract of *Daucus carota* (EEDC) formulated cream in excision and incision wound model by assessing various physicochemical, macroscopic, microscopic and biochemical parameter.

## 2. Materials and methods

### 2.1. Collection of plant material

The roots of *Daucus carota* L. were collected from rural areas of Pune district, Maharashtra in the month of October 2010. Authentication of Plant was carried out by P.G. Diwakar, Joint Director, Botanical Survey of India, Pune.

### 2.2. Preparation of extract

The fresh roots (1 kg) of *Daucus carota* were peeled, washed, cut into small pieces and homogenized in blender without adding water and extracted with 95% ethanol using soxhlet extractor, at room temperature. The ethanolic extract was filtered and concentrated by distillation process. A brownish-green colored residue was obtained which was kept in a desiccator<sup>[22]</sup>.

### 2.3. Preliminary phytochemical screening

The Preliminary phytochemical screening of the ethanolic extract of *Daucus carota* L. was carried out according to the methods described by Khandelwal *et al*<sup>[23]</sup>.

### 2.4. Animals

Healthy adult male swiss albino mice (20–30 g) and male wistar rats (230–250 g) were obtained from the National Toxicological Centre, Pune (India). The animals were housed in groups of 6 in solid bottom polypropylene cages and maintained at (24±1) °C, with relative humidity of 45–55% and 12:12 h dark/light cycle. The animals were acclimatized for a period of two weeks and were kept under pathogen free conditions. The animals had free access to standard pellet chow (Chakan Oil Mills, Sangli) throughout the experimental protocol. The animals had access to filtered water. The pharmacology and acute toxicity protocols were approved by the Institutional Animal Ethics Committee (IAEC) (522/05/ac/CPCSEA).

### 2.5. Chemicals

Anesthetic ether, ethanol, formalin sodium hydroxide, chloroform, ether, hydrochloric acid and conc. Sulphuric acid were purchased from S.D. Fine Chemicals, Mumbai, India.

### 2.6. Cream preparation for topical application

An ethanolic extract of *Daucus carota* root was used for the preparation of the cream for topical application<sup>[24]</sup>. A soft paraffin based aqueous cream of EEDC was prepared in concentration of 1%, 2% and 4% using suitable preservative and stored in refrigerator until further use.

### 2.7. Physical evaluations

Preliminary evaluation of formulations at different concentrations was carried out as follows<sup>[25]</sup>:

#### 2.7.1. pH

The pH of various formulations was determined in triplicate by using Digital pH meter<sup>[26]</sup>.

### 2.7.2. Viscosity

Viscosity measurement in triplicate was carried out using Brookfield Viscometer<sup>[27]</sup>. The viscosity values are expressed as Mean±Standard deviation.

### 2.7.3. Spreadability

Spreadability was evaluated quantitatively and qualitatively by using spreadability apparatus.

### 2.7.4. Acute skin irritation study

The primary skin irritation test was performed on albino rats (150–200 g). The animals were maintained on standard animal feed and had free access to water ad libitum. The animals were kept under standard laboratory condition. The total mass was divided into four batches, each batch containing seven animals. Two batches of each were used for control and test. Dorsal hairs at the back of the rats were clipped off one day prior to the commencement of the study. Animals showing normal skin texture were housed individually in cages with copography meshes to avoid contact with the bedding. 50 mg of the each formulation of different concentrations were applied over one square centimeter area of intact and abraded skin to different animals. Aqueous solution of 0.8% formalin was applied as standard irritant. The animals were observed for seven days for any signs of oedema and erythema.

### 2.7.5. Extrudability

The formulations were filled in the collapsible tubes after the creams were set in the container and the extrudability was determined in terms of weight (grams) required to extrude a 0.5 cm ribbon of cream in 10 second. Formulation was also evaluated for organoleptic properties.

## 2.8. Excision wound model<sup>[28,29]</sup>

Excision wound model was used for the study of rate of contraction of wound and epithelization. Animals were anaesthetized with 80 mg/kg dose of ketamine (i.p.) and the back hairs of the animals were depilated by shaving. An impression was made on the dorsal thoracic region 1 cm away from vertebral column and 5 cm away from ear on the anaesthetized rat. Excision wounds sized 300 mm<sup>2</sup> and 2 mm depth were made by cutting out layer of skin from the shaven area. Haemostasis was achieved by blotting the wound with cotton swab soaked in normal saline. The entire wound was left open. The study comprised six different groups of six animals in each groups as follows and the treatment was done topically in all the cases:

Group I– Normal animals: did not received injury for wound formation

Group II– Control animals: received injury for wound formation but did not receive any cream or drug treatment

Group III– FSC treated animals: received injury for wound

formation and treatment with Framycine sulfate cream (1% w/w)

Group IV– Drug treated animals: received injury for wound formation and treatment with *Daucus carota* ethanolic extract cream (1% w/w)

Group V– Drug treated animals: received injury for wound formation and treatment with *Daucus carota* ethanolic extract cream (2% w/w)

Group VI– Drug treated animals: received injury for wound formation and treatment with *Daucus carota* ethanolic extract cream (4% w/w)

### 2.8.1. Measurement of wound area<sup>[30]</sup>

The progressive changes in wound area were monitored by a camera (Fuji, S20 Pro, Japan) on predetermined days i.e., 2, 4, 8, 12, 16 and 20. Later on, wound area was measured by tracing the wound on a millimeter scale graph paper.

### 2.8.2. Measurement of wound contraction<sup>[31]</sup>

Wound contraction was calculated as percentage of the reduction in original wound area size. It was calculated by using following formula:

Percentage wound contraction=(Initial area of wound–N<sup>th</sup> day area of wound)/Initial area of wound×100

### 2.8.3. Determination of period of epithelization<sup>[32]</sup>

Falling of scab leaving no raw wound behind was taken as end point of complete epithelization and the days required for this was taken as period of epithelization.

### 2.8.4. Measurement of wound Index<sup>[33]</sup>

Wound index was measured daily with an arbitrary scoring system. (Table 1)

**Table 1**

An arbitrary scoring system for measurement of wound healing index.

Gross changes	Wound Index
Complete healing of wounds	0
Incomplete but healthy healing	1
Delayed but healthy healing	2
Healing has not yet been started but the environment is healthy	3
Formation of pus – evidence of necrosis	4
Total	10

### 2.8.5. Histopathological examination

A specimen sample of tissue was isolated from the skin of each group of rat were collected at the end of the experiment to evaluate for the histopathological alterations. Samples were fixed in 10% buffered formalin, processed and blocked with paraffin and then sectioned into 5 μm and stained with hematoxylin & eosin (HE), Photomicrographs were

captured at a magnification of 100 X. Sections were analyzed and scored as mild (+), moderate (++) and severe (+++) for epidermal or dermal re-modeling. Re-epithelization or Ulcus in epidermis; fibroblast proliferation, mononuclear and/or polymorphonuclear cells, neovascularization and collagen depositions in dermis were analyzed to score the epidermal or dermal re-modeling. At the end of the examination, all the wound healing processes were combined and staged for wound healing phases as inflammation, proliferation and re-modeling in all groups.

## 2.9. Incision wound model<sup>[28,29]</sup>

All the animals were anaesthetized with ketamine and the back hair of the rats were shaved by using a shaving machine. Six centimeter long, two linear-paravertebral incisions were made with a sterile surgical blade through the full thickness of the skin at the distance of 1.5 cm from the midline of each side of the vertebral column. The wounds were closed with three surgical interrupted sutures of 1 cm apart. All the sutures used in the experiments were non-absorbable braided non-capillary and siliconized. The study comprised six different groups of six animals in each groups as follows and the ointment was topically applied once in a day. The sutures were removed on 8th post wound day. The skin breaking strength, total protein and hydroxyproline content of the wounds were measured on 10th day.

Group I – Normal animals: did not receive surgery for wound formation

Group II– Control animals: received surgery for wound formation and did not receive any cream or drug treatment

Group III– FSC treated animals: received surgery for wound formation and treatment with Framycine sulfate cream (1% w/w)

Group IV– Drug treated animals: received surgery for wound formation and treatment with *Daucus carota* ethanolic extract cream (1% w/w)

Group V– Drug treated animals: received surgery for wound formation and treatment with *Daucus carota* ethanolic extract cream (2% w/w)

Group VI– Drug treated animals: received surgery for wound formation and treatment with *Daucus carota* ethanolic extract cream (4% w/w)

### 2.9.1. Measurement of tensile strength<sup>[34]</sup>

On the 10th day the animals were sacrificed and there tensile strength was measured as follows: After sacrificing the animals after anaesthesia, sutures were gently pulled out. Both wound areas from each animal were removed carefully. Wound stripes of equal size (width) were then cut using a knife in which two blades were fixed at a fixed distance. Both ends of each strip were fixed with the help of a pair of steel clips. One clip allowed hanging on a stand and a polyethylene bottle was then allowed to fill with water gradually till the wound strip was broken at the site of wound. The amount of water required to break the wound was noted and expressed as tensile strength of wound in gm.

### 2.9.2. Estimation of total protein

Protein concentration was estimated according to the method of Lowry *et al* and Kandhare *et al*<sup>[35,36]</sup>, using BSA (bovine serum albumin) as a standard.

### 2.9.3. Estimation of collagen (hydroxyproline content)<sup>[31]</sup>

Wound tissues were analyzed for hydroxyproline content, which is basic constituent of collagen. Measurement of hydroxyproline hence can be used as a biochemical marker for tissue collagen and an index for collagen turnover. For preparation of protein hydrolysate, 50 mg of tissue sample in 1.0 ml of 6.0N HCl was weighed and sealed in screw-capped glass tube. The tubes were autoclaved at 151.056 kg/ cm<sup>2</sup> for 3 h. The hydrolysate was neutralized to pH 7.0 and brought to the appropriate volume (filtered if necessary). Test tubes marked as sample, standard and blank were taken. One milliliter of test sample was added to test tubes marked as sample, 1.0 ml of DM water to test tubes marked as blank and 1.0 ml standard solutions to test tubes marked as standard. One milliliter of 0.01M copper sulphate solution was added to all the test tubes followed by the addition of 1.0 ml of 2.5N sodium hydroxide and 1.0 ml of 6% hydrogen peroxide. The solutions were occasionally mixed for 5 min and then kept for 5 min in a water bath at 80°C. Tubes were chilled in ice-cold water bath and 4.0 ml of 3.0N sulphuric acid was added with agitation. Two milliliters of p-(dimethylamino) benzaldehyde was then added and heated in water bath at temperature 70°C for 15 min. The absorbance was measured at 540 nm. The concentration of the sample was calculated as:

Concentration of the sample=OD of the sample / OD of standard × Concentration of standard

### 2.10. Data and statistical analysis

All the results were expressed as mean±S.E.M. Data analysis was performed using GraphPad Prism 5.0 software (GraphPad, San Diego, USA). Statistical comparisons were made between drug-treated groups and disease control animals. Data of disease activity index was analyzed using one-way ANOVA; Dunnett's multiple range test was applied for post hoc analysis. Whereas data of wound area and percent wound contraction was analyzed using two-way repeated ANOVA, Bonferroni's multiple range test was applied for post hoc analysis. A value of  $P < 0.05$  was considered to be statistically significant.

## 3. Results

### 3.1. Preliminary phytochemical screening

The ethanolic extract of *Daucus carota* L. root was screened for various chemical tests as per the reported methods and was found to contain Alkaloids, carbohydrates, flavonoids, protein and polyphenols. (Table 2)

**Table 2**

Preliminary phytochemical constituents present in ethanolic extract of *Daucus carota* L. root

Sr. No.	Chemical Test	Ethanolic extract of <i>Daucus carota</i> (EEDC)
1.	Alkaloids	
	Mayer test	Positive
	Wagner's test	Negative
	Hager's test	Positive
	Dragondraff's test	Negative
2.	Carbohydrates and glycosides test	
	Molisch's test	Positive
	Fehling's test	Positive
	Legal's test	Positive
	Phytosterol	
3.	Salkowski reaction	Negative
	Fixed oil	
4.	Spot test	Negative
	Phenolic compound and tannins	
5.	Ferric chloride test	Positive
	Lead acetate test	Positive
	Proteins	
6.	Million's reagent	Positive
	Flavonoids detection	Positive
7.	Saponins	
	Foam test	Negative

### 3.2. Physicochemical evaluations of different formulation of ethanolic extract of *Daucus carota* cream

The pH of the ethanolic extract of *Daucus carota* L. root cream formulation (1, 2 and 4%) was 6.48, 6.51 and 6.54 respectively which lie in normal pH range of human skin, where as the viscosity was (15.2±25), (15.3±75) and (16.1±75) cps respectively which indicated that as the torque and shear stress increases. The spreadability time of formulation (1, 2 and 4%) was 23, 23 and 25 sec. respectively. Spreadability of test formulations was compared to that of marketed formulation that is FSC. The readings indicate they are nearly same in the terms of applicability or spreading capacity. The viscosity of the formulation decreases as the spreadability increases. Acute skin irritation study of EEDC cream formulation did not produce any skin irritation, i.e., erythema and edema for about a week when applied over the skin. EEDC cream formulation also showed good homogeneity and extrudability. (Table 3)

**Table 3**

Physicochemical evaluations of different formulation of ethanolic extract of *Daucus carota* cream (mean±SD).

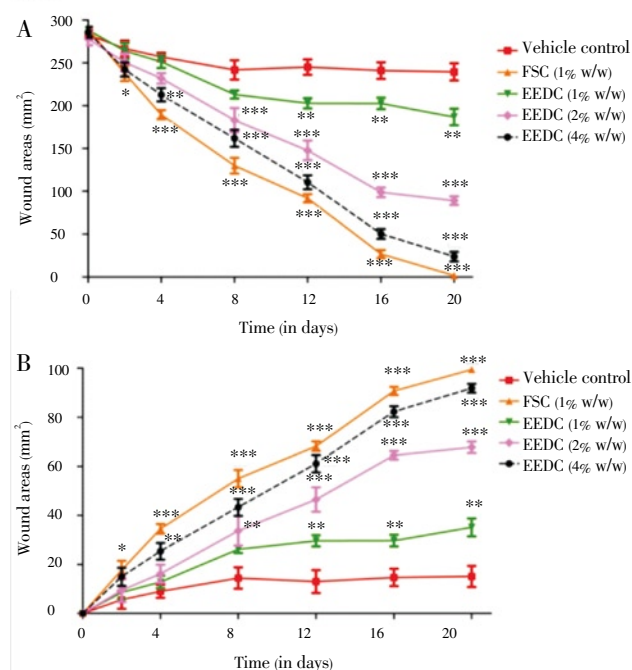
Formulations (cream) (w/w)	pH	Viscosity (cps)	Spreadability (sec)
EEDC (1%)	6.48	15.2 ± 25	23
EEDC (2%)	6.51	15.3 ± 75	23
EEDC (4%)	6.54	16.1 ± 75	25

### 3.3. Pharmacological evaluation of wound healing activity

#### 3.3.1. Effect of EEDC on wound area and percent wound

#### contraction

The wound area (mm<sup>2</sup>) in all animal groups was measured on day 0, 2, 4, 8, 12, 16 and 20. Treatment with EEDC cream formulation (1%, 2% and 4% w/w) resulted in significance and dose dependent decreased ( $P < 0.05$ ,  $P < 0.001$  and  $P < 0.001$  resp.) in wound area as compared to control group animals. The percent wound contraction rate was not altered significantly in control rats on day 0, 2, 4, 8, 12, 16 and 20 where as in EEDC cream formulation (1%, 2% and 4% w/w) treated animals resulted in significant increased ( $P < 0.05$ ,  $P < 0.001$  and  $P < 0.001$  resp.) in percent wound contraction as compared to control group animals. (Figure 1 and 2)



**Figure 1.** Effect of EEDC cream formulation treatment on wound area (mm<sup>2</sup>) and rate of wound contraction in rats

Data are expressed as mean±S.E.M. from six rats and analyze by Two Way ANOVA followed by Bonferroni's test. \* $P < 0.05$ , \*\* $P < 0.01$ , \*\*\* $P < 0.001$  as compared to control group animals

#### 3.3.2. Effect of EEDC on epithelization period

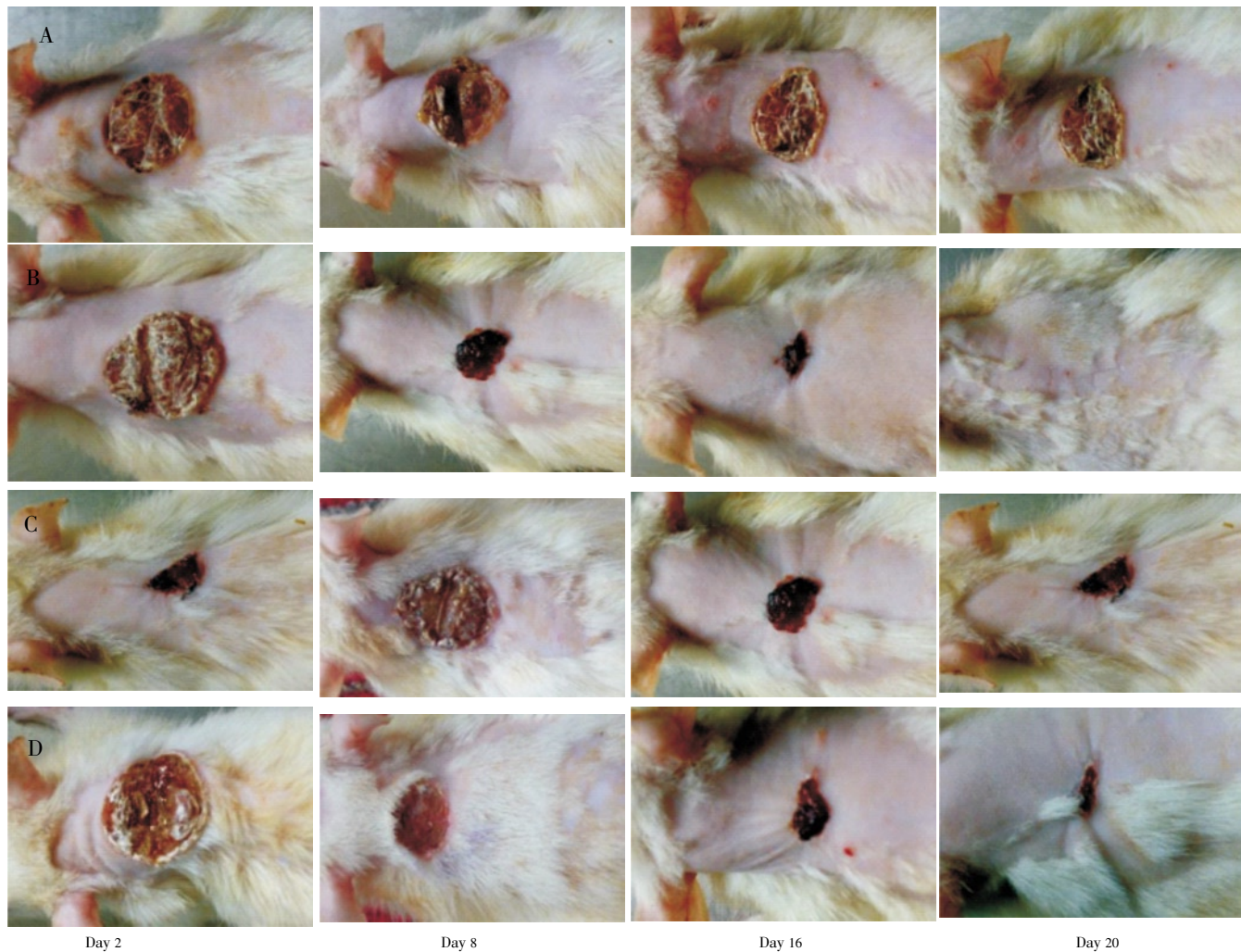
Epithelization period in control rats was 20.17 ± 0.47 days where as in EEDC cream formulation (2% and 4% w/w) treated animals it was 15.83 ± 0.47 and 13.50 ± 0.99 days respectively. Treatment with EEDC cream formulation (2% and 4% w/w) significantly decreased ( $P < 0.001$ ) epithelization period as compared to control group. (Table 4)

**Table 4**

Effect of EEDC cream formulation treatment on period of epithelization, wound index and scar width in rats.

Treatment	Period of epithelization (Day)	Wound index	Scar width (μ m)
Vehicle control	20.17 ± 0.47	3.66 ± 0.21	150.5 ± 11.04
FSC (1% w/w)	10.50 ± 0.61***	0.66 ± 0.33***	61.53 ± 4.76***
EEDC (1% w/w)	18.67 ± 0.49	2.83 ± 0.47	142.3 ± 4.33
EEDC (2% w/w)	15.83 ± 0.47***	1.66 ± 0.55*	116.6 ± 10.61**
EEDC (4% w/w)	13.50 ± 0.99***	1.16 ± 0.47**	86.37 ± 4.06***

Data are expressed as mean ± S.E.M. from six rats and analyze by one Way ANOVA followed by Dunnett's test. \* $P < 0.05$ , \*\* $P < 0.01$ , \*\*\* $P < 0.001$  as compared to control group animals



**Figure 2.** Photographs of rats showing various phases of wound healing. A: Vehicle control; B: FSC (1% w/w); C: EEDC (2% w/w); D: EEDC (4% w/w).

**Table 5**

Effect of EEDC cream formulation treatment on tensile strength, hydroxyproline content and protein content in rats

Treatment	Tensile strength (gm/cm <sup>2</sup> )	Hydroxyproline content ( $\mu$ g / 50mg tissue)	Protein content (mg/g tissue)
Vehicle control	272.1 $\pm$ 7.21	219.7 $\pm$ 10.81	46.03 $\pm$ 1.37
FSC (1% w/w)	618.7 $\pm$ 10.61***	526.3 $\pm$ 13.27***	80.67 $\pm$ 2.50***
EEDC (1% w/w)	301.7 $\pm$ 13.32	242.7 $\pm$ 20.08	48.67 $\pm$ 2.31
EEDC (2% w/w)	426.0 $\pm$ 13.21**	302.8 $\pm$ 21.77**	58.53 $\pm$ 1.18**
EEDC (4% w/w)	515.1 $\pm$ 9.58***	494.5 $\pm$ 18.08***	75.23 $\pm$ 1.56***

Data are expressed as mean  $\pm$  S.E.M. from six rats and analyze by one Way ANOVA followed by Dunnett's test. \* $P < 0.05$ , \*\* $P < 0.01$ , \*\*\* $P < 0.001$  as compared to control group animals.

**Table 6**

Wound healing processes and healing phases of the control, FSC (1% w/w) and EEDC cream formulation (1%, 2% and 4% w/w) treated animals

Histopathological observations	Vehicle control	FSC (1% w/w)	EEDC (1% w/w)	EEDC (2% w/w)	EEDC (4% w/w)
Scab	+++	+	+++	++	+
Ulcer	+++	-	+++	+	+
Re-epithelization	-	+++	-	+	++
fibroblast proliferation	+++	-	+++	++	+
mononuclear cells	++	+	++	+	-
Polymorphonuclear cells	+++	-	+++	++	+
Neovascularization	+++	-	++	+	+
Inflammation phase	+++	+	+++	+	-
Proliferation phase	++	++	++	+	++
Re-modeling phase	-	+++	-	+	++

### 3.3.3. Effect of EEDC on wound index

In vehicle control animals wound index was  $3.66 \pm 0.21$  where as in EEDC cream formulation (2% and 4% w/w) treated animals it was  $1.66 \pm 0.55$  and  $1.16 \pm 0.47$  respectively. EEDC cream formulation (2% and 4% w/w) treated animals significantly and dose dependently ( $P < 0.05$  and  $P < 0.01$ ) decreased wound index as compared to control group. (Table 4)

### 3.3.4. Effect of EEDC on scar formation

The scar width in vehicle control animal was  $150.5 \pm 11.04$   $\mu\text{m}$  where as in EEDC cream formulation (2% and 4% w/w) treated animals scar width was  $116.6 \pm 10.61$  and  $86.37 \pm 4.06$   $\mu\text{m}$  respectively. Treatment with EEDC cream formulation (2% and 4% w/w) significantly and dose dependently ( $P < 0.01$  and  $P < 0.001$  respectively) decreased scar width as

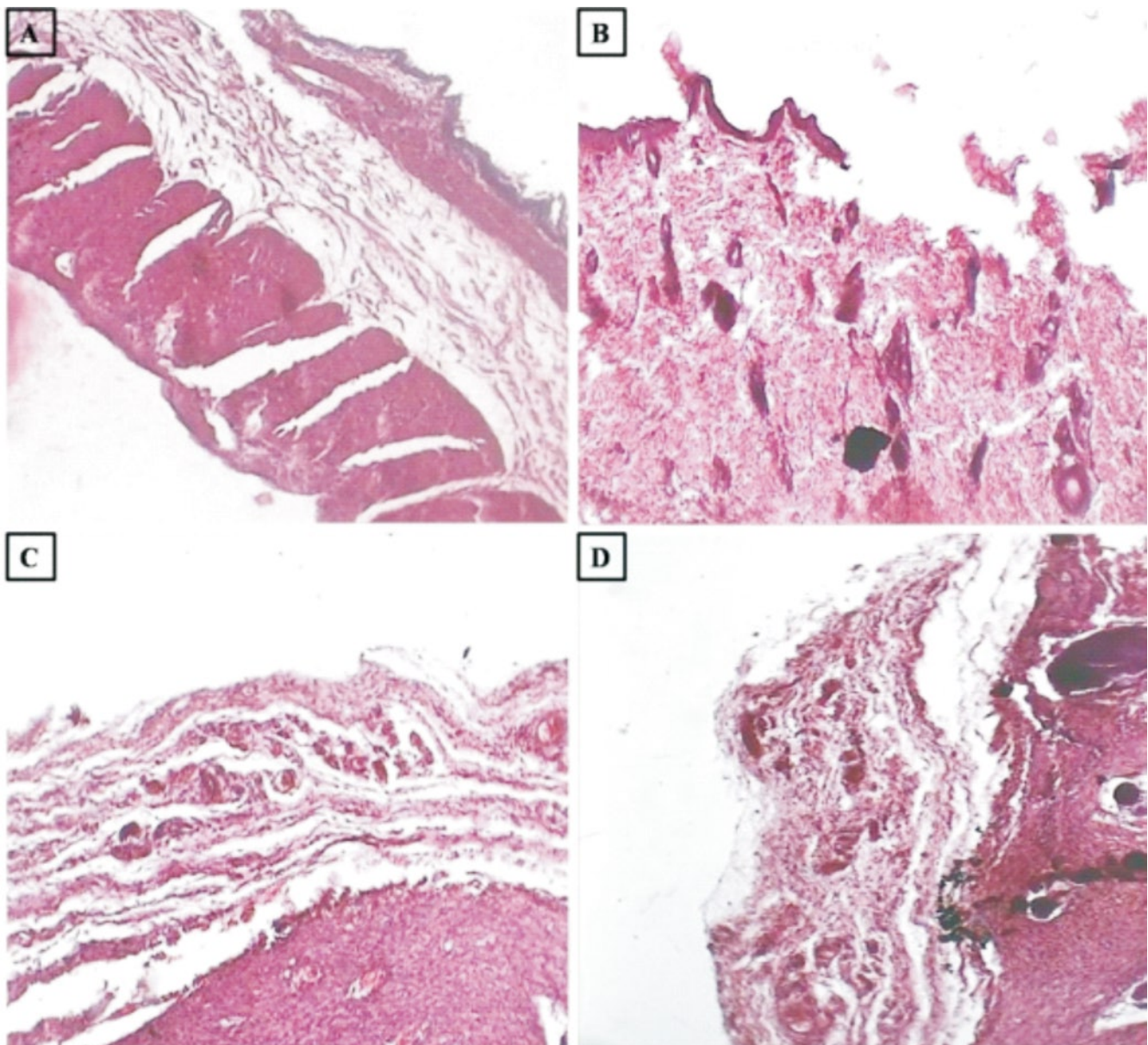
compared to control group. (Table 4)

### 3.3.5. Effect of EEDC on tensile strength

In vehicle control animal tensile strength was  $272.1 \pm 7.21$   $\text{gm/cm}^2$  where as in EEDC cream formulation (2% and 4% w/w) treated animals tensile strength was  $426.0 \pm 13.21$  and  $515.1 \pm 9.58$   $\text{gm/cm}^2$  respectively. Treatment with EEDC cream formulation (2% and 4% w/w) significantly and dose dependently ( $P < 0.01$  and  $P < 0.001$  respectively) increased tensile strength as compared to control group. (Table 5)

### 3.3.6. Effect of EEDC on hydroxyproline and protein content

The hydroxyproline content in vehicle control animal was  $219.7 \pm 10.81$   $\mu\text{g}/50\text{mg}$  tissue where as in EEDC cream formulation (2% and 4% w/w) treated animals it was  $302.8 \pm 21.77$  and  $494.5 \pm 18.08$   $\mu\text{g}/50\text{mg}$  tissue respectively. In



**Figure 3.** Photomicrographs of sections of skin from rats stained with H & E.

Skin microscopic image of (A) normal rat (B) wound control rat (C) FSC (1% w/w) treated rat (D) EEDC cream formulation (4% w/w) treated rat. Images (100 $\times$  magnification) are typical and representative of each study group.

vehicle control animals protein content was  $46.03 \pm 1.37$  mg/g tissue where as in EEDC cream formulation (2% and 4% w/w) treated animals protein content was  $58.53 \pm 1.1$  and  $75.23 \pm 1.56$  mg/g tissue. Treatment with EEDC cream formulation (2% and 4% w/w) significantly and dose dependently ( $P < 0.01$  and  $P < 0.001$  respectively) increased hydroxyproline and protein content as compared to control group. (Table 5)

### 3.3.7. Histopathological Examination

Inflammation, proliferation and remodeling are the various phases in wound healing processes that were observed during the experimental period. Delayed in wound healing processes along with edema, monocyte cells and cellular necrosis were recorded in control groups. Aggregation of macrophages with poor collagenation was observed in histological examination of control group animals. The large numbers of fibroblasts were observed in the dermis and less new blood vessels formations were observed in control. In EEDC cream formulation treated group proliferation of collagen, fibrous tissue and capillaries with epidermal covering at the margin of wound were observed. Treatment with EEDC cream formulation resulted in decrease inflammation, increasing the rate of tissue perfusion and proliferation as well as re-modeling, along with re-epithelization. The reduced macrophages and increased collagen fibers with low scar formation were observed in the EEDC cream formulation treated animals. (Figure 3 and Table 6)

## 4. Discussion

Contraction, wound closure and restoration of the functional barrier are the various phases of wound healing. Wound healing is the body's natural process of regenerating dermal and epidermal tissue[25,32].

The healing primarily depends on the repairing ability of the tissue in addition to type and degree of damage and general health status of the tissue. Cream is the most preferable form of dosage form as it is the most convenient form of topical application[6,32]. Therefore the aim of present investigation was to formulation and evaluation of ameliorative effect of ethanolic extract of *Daucus carota* root cream formulation on experimentally induced wounds in rats. Spreadability and consistency are the two different parameters that decide suitability of an ointment for the topical application[7,33]. Therefore, examination of these parameters suggested that formulation is suitable for topical application.

Edema, fibroblast, collagen and new blood vessels are the primary component of the granulation tissue of the wound. At the site of injury when platelet comes into the contact with exposed collagen to release the clotting factors which might have resulted in formation of fibrin clot. This fibrin clot can serve as a provisional matrix which ultimately healed the wound[42]. For the tissue repair collagen deposition can be necessary event that might have occurred through the released of fibroblast which is a connective tissue[43,44]. Collagen is an important part of the wound healing process

as it required for repair and restores normal structure and function after tissues damage[45,46].

In the various types injuries like burn, inflicted wound and skin ulcers lipid peroxidation is an vital process. The viability of collagen fibrils is increased by inhibiting lipid peroxidation which ultimately increases the strength of collagen fibers. Is also prevents the cell damage and promotes the DNA synthesis[47–54]. Treatment with EEDC might have increased the rate of wound healing. Wound healing effects may be due to regulation of collagen expression and an increase in tensile strength of the wounds by inhibiting the elevated levels of lipid peroxides. The result of present investigation was coincided with the earlier works[55,56]. Enhanced healing activity has been attributed to increased collagen formation and angiogenesis. Angiogenesis in granulation tissues improves blood supplementation to the wound site, thus providing nutrients and oxygen essential for the healing process.

It has been documented that flavonoids possess the therapeutic potential like anti-inflammatory, anti-fungal, antioxidant as well as wound healing[34,57]. Moreover, flavonoids and their derivatives are known to decrease lipid peroxidation by improving vascularity and by preventing or slowing down the progress of cell necrosis[58,59]. It has been shown to increase collagen synthesis, promote the cross-linking of collagen, decrease the degradation of soluble collagen, accelerate the conversion of soluble collagen to insoluble collagen, and inhibits the catabolism of soluble collagen[60]. Facilitating oxygen diffusion, increasing lymphatic drainage, diminishing oxygen free radical overproduction and increasing the collagen synthesis were together found to improve healing[61]. The phytochemical analysis of ethanolic extract of *Daucus carota* L. root revealed the presence of flavonoids and phenolic acid derivatives. Therefore, wound-healing potential of *Daucus carota* may be attributed to the phytoconstituents present in the ethanolic extract of *Daucus carota* L. root, which may be either due to their individual or additive effect that speeds up the process most probably the proliferation phase of wound healing.

When wound occurs, it is exposed to external environmental and is prone to attack by microbes which invade the wound[62,63]. Common wound contaminants include *Escherichia coli*, *Staphylococcus aureus*, *Streptococcus faecalis*, *Pseudomonas aeruginosa* and *Clostridium perfringens*, *Clostridium tetani* and *Coliform bacilli*. The free radicals which were generated at the site of injury may protect the wound from invasion by microbes[64,65]. If a wound becomes infected, the acute phase of inflammation becomes pronounced leading to further production of tissues oxidants which damage cellular membranes, DNA, proteins, lipid and extracellular matrix[66,67]. It has been reported that alcoholic extract of *Daucus carota* possess antimicrobial potential which may help in the speeds up the process of wound healing[15].

The wound-healing property of ethanolic extract of *Daucus carota* L. root may be attributed to potential. However, further phytochemical studies are needed to isolate the active compound(s) responsible for these pharmacological activities. Further studies with purified constituents are



needed to understand the complete mechanism of wound healing activity of *Daucus carota*.

### Conflict of interest statement

We declare that we have no conflict of interest.

### Acknowledgements

The authors would like to acknowledge Prof. R. D. Patankar, Principal, Abhinav College of Pharmacy and Dr. S. L. Bodhankar, Professor and Head, Department of Pharmacology, Poona College of Pharmacy, Bharati Vidyapeeth Deemed University, Pune, India for their constant support and valuable suggestions for the research work. We are also thankful to Dr. Vasant Narke, Director, TOXINDIA, Pune, India for providing necessary facilities to carry out the study. We are also thankful to the All India Council of Technical and Education (AICTE), India (Ref. No. PG/GATE–SCM/2004–2005/G–39, Dated: 11/02/2011) for financial support by awarding GATE Scholarship to one of the author Mr. Kandhare Amit for the research work.

### References

- [1] Kumari M, Eesha BR, Amberkar M, babu S, Rajshekar KN. Wound healing activity of aqueous extract of *Crotalaria verrucosa* Wistar albino rats. *Asian Pac J Trop Med* 2010; **3**(10): 783–787.
- [2] Silambujanaki P, Chandra CT, Kumar KA, Chitra V. Wound healing activity of *Glycosmis arborea* leaf extract in rats. *J Ethnopharmacol* 2010; **134**(1): 198–201.
- [3] Nagda D, Saluja A, Nagda C. Antioxidant activities of methanolic and aqueous extracts from leaves of *Martynia annua* Linn. *Pharmacogn J* 2009; **1**(4): 288–287.
- [4] Garg VK, Paliwal SK. Wound–healing activity of ethanolic and aqueous extracts of *Ficus benghalensis*. *J Adv Pharm Tech Res* 2011; **2**: 110–114.
- [5] Thring T, Hili P, Naughton DP. Anticollagenase, antielastase and antioxidant activities of extracts from 21 plants. *BMC Complement Altern Med* 2009; **9**: 17–27.
- [6] Narayan S, Sasmal D, Mazumder PM. Evaluation of the wound healing effect of herbal ointment formulated with *Salvia splendens* (scarlet sage). *Int J Pharm Pharm Sci* 2011; **3**(3): 195–199.
- [7] Ghosh P, Kandhare AD, Gauba D, Raygude KS, Bodhankar SL. Determination of efficacy, adverse drug reactions and cost effectiveness of three triple drug regimens for the treatment of *H. pylori* infected acid peptic disease patients. *Asian Pac J Trop Biomed* 2012. In press.
- [8] Esimone CO, Nworu CS, Jackson CL. Cutaneous wound healing activity of an herbal ointment containing the leaf extract of *Jatropha curcas* L. (Euphorbiaceae). *Int J App Res Nat Prod* 2009; **1**(4): 1–4.
- [9] Gosavi TP, Ghosh P, Kandhare AD, Bodhankar SL. Unwrapping Homeopathic principles in the wake of research: serendipity, placebo or true therapeutic milestones. *Pharmacologyonline* 2011; **1**: 894–906.
- [10] Gavimath CC, Sudeep HV, Sujjan Ganapathy PS, Padmalatha Rai S, Ramachandra YL. Evaluation of wound healing activity of *Butea Monosperma* Lam. extracts on rats. *Pharmacologyonline* 2009; **2**: 203–216.
- [11] Kandhare AD, Raygude KS, Ghosh P, Gosavi TP, Bodhankar SL. Patentability of animal models: india and the globe. *Int J Pharm Biol Arc* 2011; **2**(4): 1024–1032.
- [12] Ramachandra YL, Kavitha BT, Padmalatha Rai S, Vedamurthy AB, Shruthi SD. Investigation of wound healing activity of extracts from *Tinospora cordifolia*. *Deccan J Pharmacology* 2011; **2**(2): 43–53.
- [13] Barnes J, Anderson LA, Phillipson JD. Editors, Herbal medicine. 3rd ed. Pharmaceutical Press, London, 2002, p. 593–5.
- [14] Thomas KJ, Nicholl JP, Coleman P. Use and Expenditure pm Complementary Medicine in England: A population based survey. *Complement Ther Med* 2001; **9**(1): 2–11.
- [15] Prochezhian E, Ansari SH. Analgesic and anti–inflammatory activity of volatile oil from *Daucus carota* Linn. *Indian J Nat Prod* 2000; **16**: 24–26.
- [16] Bishayee A, Sarkar A, Chaterjee M. Hepatoprotective activity of carrot against carbon tetrachloride intoxication in mouse liver. *J Ethnopharmacol* 1995; **47**: 69–74.
- [17] Neef H, Declercq P, Laekeman G. Hypoglycaemic activity of selected European plants. *Phytother Res* 1995; **9**: 45–8.
- [18] Wehbe K, Mroueh M, Daher CF. The Potential Role of *Daucus carota* Aqueous and Methanolic Extracts on Inflammation and Gastric Ulcers in Rats. *J Complement Integ Med* 2009; **6**(1): 7.
- [19] Prakash AO. Biological Evaluation of some medicinal plant extracts for contraceptive efficacy. *Contracept Deliv Syst* 1984, **5**: 9.
- [20] Diab–Assaf M, Mroueh M, El–Sharif S. Evaluation of anti–cancer effect of *Daucus carota* on the human promyelocytic leukemia HL–60 cells. AACR International Conference on Molecular Diagnostics in Cancer Therapeutic Development, Atlanta, USA, 2007.
- [21] Abou Zeinab RM, Mroueh M, Daher CF. Potent anti–tumor promoting effects of *Daucus carota* oil extract in mice. *Planta Medica* 2008, **74**: 1008.
- [22] Patil MVK, Kandhare AD, Bhise SD. Anti–inflammatory effect of *Daucus carota* root on experimental colitis in rats. *Int J Pharm Pharm Sci* 2012; **4**(1): 337–343.
- [23] Khandelwal KR. Practical Pharmacognosy. Technique and Experiments. 8th Ed. Pune: Nirali Prakashan, 2007, p. 149–53.
- [24] Gaud RS, Gupta GD. Practical Pharmaceutics. New Delhi: CBS Publication, 2006, p. 25.
- [25] Panda P, Nayak SS, Mohanty A, Panda DP, Panda PK. Formulation and evaluation of topical dosage form of *Pandanus fascicularis* Lamk. and their wound healing activity. *J Pharm Res* 2009; **2**(4), 630–635.
- [26] Derle DV, Sagar BSH, Kotwal RS, Ingole RD, Chavhan SS. A comparative in vitro evaluation of transdermal preparation of valdecoxib and its complex with HP– $\beta$ –cyclodextrin from microemulsion based gel. *Indian Drugs* 2006; **43**(8): 625–628.
- [27] Kim JY, Song JY, Lee EJ, Park SK. Rheological properties and microstructure of carbopol gel network system. *Colloid Polymer Sci* 2003; **281**: 614–623.
- [28] Nirmala S, Karthiyayini T. Wound healing activity on the leaves of *Achillea millefolium* L. by excision, incision, and dead space model on adult wistar albino rats. *Int Res J Pharm* 2011; **2**(3): 240–245.
- [29] Patil MK, Kandhare AD, Bhise SD. Pharmacological evaluation of ameliorative effect of aqueous extract of *Cucumis sativus* L. fruit formulation on wound healing in Wistar rats. *Chron Young Sci* 2011; **2**: 207–213.
- [30] Nalwaya N, Pokharna G, Deb L, Jain NK. Wound healing activity of latex of *Calotropis gigantea*. *Int J Pharm Pharm Sci* 2009; **1**(1): 176–181.
- [31] Sharma S, Sikarwar MS. Wound healing activity of ethanolic extract of leaves of *Eclipta alba*. *Pharmacog Magazine* 2008; **4**(13): 108–111.
- [32] Suntar IP, Akkol EK, Keles H, Oktem A, Baser KHC, Yesilada E.

- A novel wound healing ointment: A formulation of Hypericum perforatum oil and sage and oregano essential oils based on traditional Turkish knowledge. *J Ethnopharmacol* 2011; **134**: 89–96.
- [33] Altiok D, Altiok E, Tihminlioglu F. Physical, antibacterial and antioxidant properties of chitosan films incorporated with tyme oil for potential wound healing applications. *J Mater Sci Mater Med* 2010; **21**: 2227–2236.
- [34] Akkol EK, Koca U, Pesin I, Yilmazer D, Toker G, Yesilada E. Exploring the wound healing activity of *Arnebia densiflora* (Nordm.) Ledeb. by in vivo models. *J Ethnopharmacol* 2009; **124**: 137–141.
- [35] Lowry OH, Rosenbrough NJ, Farr AC, Randell RJ. Protein measurement with folin–phenol reagent. *J Biol Chem* 1951; **193**: 265–275.
- [36] Kandhare AD, Raygude KS, Ghosh P, Ghule AE, Bodhankar SL. Neuroprotective effect of naringin by modulation of endogenous biomarkers in streptozotocin induced painful diabetic neuropathy. *Fitoterapia* 2012; **83**: 650–659.
- [37] Neves JM, Matosa C, Moutinho C, Queirozd G, Gomesa LR. Ethnopharmacological notes about ancient uses of medicinal plants in Tras-os-Montes (northern of Portugal). *J Ethnopharmacol* 2009; **124**: 270–283.
- [38] Suntar IP, Akkol EK, Yalcin FN, Koca U, Keles H, Yesilada E. Wound healing potential of *Sambucus ebulus* L. leaves and isolation of an active component, quercetin 3-O-glucoside. *J Ethnopharmacol* 2010; **129**(1): 106–14.
- [39] Kandhare AD, Raygude KS, Ghosh P, Ghule AE, Gosavi TP, Badole SL, Bodhankar SL. Effect of hydroalcoholic extract of *Hibiscus rosa sinensis* Linn. leaves in experimental colitis in rats. *Asian Pac J Trop Biomed* 2012; **5**: 337–344.
- [40] Kandhare AD, Raygude KS, Ghosh P, Bodhankar SL. The ameliorative effect of fisetin, a bioflavonoid, on ethanol-induced and pylorus ligation-induced gastric ulcer in rats. *Int J Green Pharm* 2011; **5**: 236–243.
- [41] Li S, Zhao J, Liu J, Xiang F, Lu D, Liu B et al. Prospective randomized controlled study of a Chinese herbal medicine compound Tangzu Yuyang ointment for chronic diabetic foot ulcer: A preliminary report. *J Ethnopharmacol* 2011; **133**: 543–50.
- [42] Patil MVK, Kandhare AD, Bhise SD. Effect of aqueous extract of *Cucumis sativus* Linn. fruit in ulcerative colitis in laboratory animals. *Asian Pac J Trop Biomed* 2012. In press.
- [43] Nguyen DT, Orgill DP, Murphy GF. The Pathophysiologic Basis for wound healing and cutaneous regeneration: Biomaterials for treating skin loss. Wood head publishing (UK/Europe) & CRC Press (US), Cambridge/Boca Raton: 2009. p. 25–57.
- [44] Bele A, Jadhav V, Kadum VJ. Wound healing activity of herbal formulation. *J Pharm Res* 2009; **2**(2): 344–48.
- [45] Agarwal PK, Singh A, Gaurav K, Goel S, Khanna HD, Goel RK. Evaluation of wound healing activity of extracts of Plantain banana (*Musa sapientum* var. paradisiaca) in rats. *Indian J Exp Biol* 2009; **47**: 32–40.
- [46] Jain S, Jain N, Tiwari A, Balekar N, Jain DK. Simple evaluation of wound healing activity of polyherbal formulation of roots of *Ageratum conyzoides* L. *Asian J Research Chem* 2009; **2**(2):135–8
- [47] Gosavi TP, Kandhare AD, Ghosh P, Bodhankar SL. Anticonvulsant activity of *Argentum metallicum*, a homeopathic preparation. *Der Pharmacia Lettre* 2012; **4**(2): 626–637.
- [48] Gosavi TP, Kandhare AD, Raygude KS, Ghosh P, Bodhankar SL. A comparative study on the efficacy, safety and cost effectiveness of *Viscum album* and *Rauwolfia serpentina* mother tincture in hypertensive patients. *Deccan J. Natural Products* 2011; **2**(3): 29–35.
- [49] Kandhare AD, Raygude KS, Ghosh P, Ghule AE, Bodhankar SL. Therapeutic role of curcumin in prevention of biochemical and behavioral aberration induced by alcoholic neuropathy in laboratory animals. *Neurosci Lett* 2012; **511**: 18–22.
- [50] Senel O, Cetinkale O, Özbay G, Ahecioglu F, Bulan R. Oxygen free radicals impair wound healing in ischemic rat skin. *Ann Plast Surg* 1997; **39**: 516.
- [51] Shetty S, Udupa S, Udupa L. Evaluation of antioxidant and wound healing effects of alcoholic and aqueous extract of *Ocimum sanctum* Linn in rats. *Evid Based Complement Alternat Med* 2008; **5**: 95–101.
- [52] Patil MVK, Kandhare AD, Bhise SD. Anti-arthritis and anti-inflammatory activity of *Xanthium srtumarium* L. ethanolic extract in Freund's complete adjuvant induced arthritis. *Biomed Aging Pathol* 2012; **2**: 6–15.
- [53] Raygude KS, Kandhare AD, Ghosh P, Ghule AE, Bodhankar SL. Evaluation of ameliorative effect of quercetin in experimental model of alcoholic neuropathy in rats. *Inflammopharmacol* 2012 DOI 10.1007/s10787-012-0122-z.
- [54] Santram L, Singhai AK. Preliminary pharmacological evaluation of *Martynia annua* Linn leaves for wound healing. *Asian Pac J Trop Biomed* 2011; **4**: 421–427.
- [55] Balasubramaniam P, Pari L, Menon VP. Protective effect of carrot (*Daucus carota* L.) against lindane – induced hepatotoxicity in rats. *Phytother Res* 1998; **12**(6): 434–436.
- [56] Patel MR, Patel LJ, Patel RK. Protective effect of *Daucus carota* root extract against renal ischemia reperfusion injury in rats. *Pharmacologyonline* 2011; **1**: 432–439.
- [57] Nayak BS, Sandiford S, Maxwell A. Evaluation of the wound-healing activity of ethanolic extract of *Morinda citrifolia* L. leaf. *Evid Based Complement Alternat Med* 2009; **6**(3): 351–356.
- [58] Patil MVK, Kandhare AD, Ghosh P, Bhise SD. Determination of role of GABA and nitric oxide in anticonvulsant activity of *Fragaria vesca* L. ethanolic extract in chemically induced epilepsy in laboratory animals. *Orient Pharm Exp Med* 2012; In Press DOI 10.1007/s13596-012-0072-4.
- [59] Raygude KS, Kandhare AD, Ghosh P, Bodhankar SL. Anticonvulsant effect of fisetin by modulation of endogenous biomarkers. *Biomed Prev Nutr* 2012; In press <http://dx.doi.org/10.1016/j.bionut.2012.04.005>.
- [60] Udegbunam RI, Udegbunam SO, Ugwuanyi SC. The wound healing potential of the ethanol extract of *Bridelia Ferruginea* Benth–In-vivo study. *J Pharm Biomed Sci* 2011; **6**(17): 1–4.
- [61] Inan A, Sen M, Koca C, Akpınar A, Dener C. The effect of purified micronized flavonoid fraction on the healing of anastomoses in the colon in rats. *Surg Today* 2006; **36**: 818–822.
- [62] Ghosh P, Kandhare AD, Raygude KS, Gauba D, Gosavi TP, Bodhankar SL. Cigarette smoking and H. pylori infection: A meta-analysis of literature. *Der Pharmacia Lettre* 2012; **4**(1): 128–134.
- [63] Raygude KS, Kandhare AD, Ghosh P, Gosavi TP, Bodhankar SL. Consumption of Alcohol and H. pylori infection: A Cumulative Meta-Analysis of Literature. *Asian J Biochem Pharm Res* 2011; **3**(1): 338–345.
- [64] Shivare Y, Singour PK, Patil UK, Pawar RS. Wound healing potential of methanolic extract of *Trichosanthes dioica* Roxb (fruits) in rats. *J Ethnopharmacol* 2010; **127**: 614–619.
- [65] Ghosh P, Kandhare AD, Gauba D, Raygude KS, Bodhankar SL. Determination of efficacy, adverse drug reactions and cost effectiveness of three triple drug regimens for the treatment of H. pylori infected acid peptic disease patients. *Asian Pac J Trop Biomed* 2012. In press.
- [66] Olugbuyiro JAO, Abo KA, Leigh OO. Wound healing effect of *Flabellaria paniculata* leaf extract. *J Ethnopharmacol* 2010; **127**: 786–788.
- [67] Gosavi TP, Ghosh P, Kandhare AD, Bodhankar SL. Therapeutic effect of H. pylori nosode in healing of chronic H. pylori infected ulcers in laboratory animals. *Asian Pac J Trop Dis* 2012. In press.